

S. Saccomanno, G. Antonini, L. D'Alatri<sup>1</sup>,  
M. D'Angelantonio<sup>2</sup>, A. Fiorita<sup>1</sup>, R. Deli

Catholic University "A. Gemelli", Rome, Italy

<sup>1</sup> Otorhinolaryngologist

<sup>2</sup> Logopaedist

e-mail: sabinasaccomanno@hotmail.it

## Causal relationship between malocclusion and oral muscles dysfunction: a model of approach

### ABSTRACT

**Aim** Bad habits result in altered functions which with time can cause anomalies of the orofacial morphology. To solve these problems, orthodontic treatment can be supported by myofunctional therapy in order to recover the normal functionality of the oral muscles. The aim of this study is to assess the need to treat patients with neuromuscular disorders, from both the occlusion and the muscles condition approach in order to obtain the balance needed for the stability of treatment.

**Materials and methods** A sample of 23 patients with atypical swallowing was included in this study, some of them presented thumb sucking and oral breathing. After case history collection, in order to make a correct orthodontic and functional diagnosis, correction of anomalies was carried out since they could compromise the success of the therapy (maxillary contraction, oral breathing, and short lingual fraenum). Then a different therapeutic approach was applied on the basis of the specific dental features.

**Results** Both from the diagnostic and therapeutic point of view, important results were achieved especially through muscle analysis with dynamometer and surface electromyography.

**Conclusion** Orthodontic therapy, in the presence of bad habits, is not enough to solve orthodontic issues, it must be combined with a myofunctional treatment. The success of the therapy is granted only when patient's and their family comply with the treatment

and all factors which can prevent success of the therapy are removed.

**Keywords** Malocclusion; Myofunctional therapy; Oral habits.

## Introduction

The craniofacial structure changes with time: it is not just made up of bones and muscles, as other parts of the body, but it also includes teeth which affect its structural development. Two variables play a role during growth: genetics and function. The morphofunctional balance is given by the combination of these factors.

With regard to genetics, science there is still much to learn. An altered function can be modified. Therefore myofunctional therapy is an efficient support for orthodontics, because altered functional conditions can cause irreversible anomalies to the facial morphology.

## Materials and methods

A sample of 23 patients (10 males and 13 females aged between 5 and 17 years) was examined at our Orthodontic Department; all patients had atypical swallowing and incorrect tongue positioning. A selected sample of 16 patients underwent rapid palatal expansion followed by speech therapy, while 7 underwent only speech therapy.

### Diagnostic protocol

For each subject the following were collected: extraoral and intraoral pictures, orthodontic models, X-rays (orthopantomography, lateral cephalogram), cephalometric analysis for examination of sagittal analysis, vertical analysis, cross-analysis, intraoral examination, extraoral examination (labial competence, lower lip interposition, chin muscle contraction). Patients also underwent assessment of the force of the orbicular muscle using dynamometer measurements [Ferrante, 2004], assessment of tongue thrust using fluorescein coloring [Ferrante, 2004], and electromyographic examination of the orofacial muscles [Ferrario, 1996, 2000]. The same examinations were repeated after therapy in order to verify possible changes in the muscle tone.

### Therapeutic protocol

The first therapeutic step was correction of problems that emerged from examinations and could potentially cause a therapeutic failure, namely:

- › contraction of the palate;

- › short lingual fraenum;
- › hypertrophy of adenoids, tonsils and/or turbinates;
- › allergic rhinitis.

For contraction of the palate a rapid expander was used. For short lingual fraenum (ankyloglossia) surgical intervention was performed. For hypertrophy of the adenoids, tonsils and/or turbinates surgical and/or pharmacological intervention was performed before speech therapy. For allergic rhinitis the treatment is pharmacological.

When deciding to start the therapy before or after myofunctional orthodontic treatment, the values of overjet and overbite should be taken into consideration.

### Recommended Therapeutic Protocol

- › Open bite: the therapeutic priority, in the case of overbite  $\leq 2$  mm, is represented by the need to close, even only partially, the bite before starting the speech therapy, by the application of a fixed grid/tongue crib. This allows both a reflected movement of the tongue, which will tend to be placed in the upper and posterior region of the mouth during swallowing. The closing of the bite is important to prepare the patient for intercuspidation during swallowing. After obtaining a partial closing of the bite, in case of overbite  $\geq 1$  mm, speech therapy is used for functional rehabilitation [Cozza, 2007].
- › Overjet: in case of overjet  $\geq 4$  mm in skeletal Class I patients should undergo myofunctional treatment instead of grid or tongue crib therapy, which would further increase the overjet [Meyer-Marcotty, 2007]. In the case of overjet  $\geq 4$  mm in skeletal Class II, patients need myofunctional therapy along with the application of an orthodontic appliance which would help the correct skeletal development [Panigrahi, 2009; Ong, 2005]. In case of overjet  $\leq 0$  mm, patients usually undergo myofunctional rehabilitation with speech therapy (20 sessions with a speech therapist and exercises to be performed at home every day) first, and then orthodontic therapy to rectify any incorrect dental position.

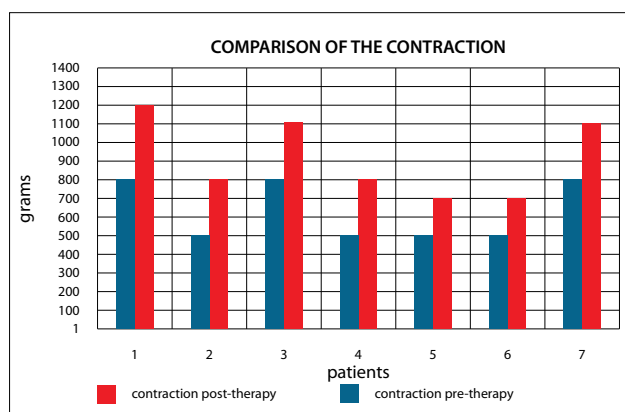


FIG. 1 Comparison between contraction of the orbicular muscle before and after therapy.

## Results

The clinical analysis shows that all patients, before therapy, had lower contraction values of the orbicular muscle compared with those found in literature (1300-1500 gr) [Ferrante, 2004]. In the 7 patients that underwent speech therapy we observed an increase of the strength of the orbicular muscle (Fig. 1).

The results of the statistical analysis, on the basis of the electromyographic values obtained according to gender, age, vertical analysis in the skeletal Class I and in skeletal Class II, cross analysis of the skeletal Class I and in skeletal Class II and the rotational type, were analysed by means of ANOVA test (Tables 1-3). The value of p was set at 0.05. The analysis shows significant statistical differences in two cases.

- a) Within the skeletal Class I subjects, the Average of the Activation Index (which compares the muscular activity of masseter and temporalis muscles) values in the open bite is lower than the normal bite position; in other words, the temporalis muscle activity resulted to be higher than that of the masseter muscles.
- b) Within the skeletal Class II subjects, the average of POC (index of the symmetric distribution of the muscular activity determined by the occlusion)  $>6$  values in the contraction of the palate is lower than when there is no contraction.

## Discussion

In the last twenty years there has been a growing clinical interest towards myofunctional therapy as confirmed by several papers on the subject [Ferrante 2004, 1994]. However the therapeutic efficacy of myofunctional treatment has not been proved yet.

Sample selection: during this study we realised the relevance and frequency of atypical swallowing and the orthodontic relapses observed are a very important objective fact, since they were caused by the persistence of untreated atypical swallowing. Despite its incidence, this bad habit is often unrecognized by patients and

CATEGORIES	P-VALUE
Gender	0.67
Age	0.25
I sk-vert	0.18
II sk-vert	0.60
I sk-cross	0.35
II sk-cross	0.03
Rot type	0.34

TABLE 1 Statistical significance.

CATEGORIES	P-VALUE
Gender	0.25
Age	0.80
I sk-vert	0.02
II sk-vert	0.36
I sk-trasv	0.53
II sk- trasv	0.12
Rot type	0.26

TABLE 2 Statistical significance of Activation Index.

underrated by specialists: we should not wonder that during our year-long study, the sample included only 23 patients with atypical swallowing. Compliance is very important for treatment success. Alterations of values were highlighted just in the activation index of patients with open bite and in the POC of patients with contraction of the palate. In the case of open bite, the occlusal contacts should be in the back; for this reason we expect a positive activation index in favour of the masseter muscles, during the maximum clenching of the jaw. The results obtained show the opposite in the case of atypical swallowing. The explanation could be that, during swallowing, the tongue tends to be placed before the arches in order to create a front seal; this would cause a lack of contact in the back part and consequently a weaker activation of the masseter muscle. Therefore, in these patients, hypotonic masseter muscles seem to be more relevant than a posterior occlusal centre of mass caused by the front anomaly. In the case of contraction of the palate, the final results show asymmetrical muscle activation (POC). This is due to the fact that since these patients are young, they have an unstable occlusion because there is no dentoalveolar compensation of the skeletal contraction. This causes an asymmetrical activation of masseter muscles, which develop greater strength in intercuspitation, and consequently an asymmetrical activation of the temporal muscles which help to steady the jaw and compensate masseter asymmetry.

## Conclusion

Atypical swallowing is very common and, if it is not corrected early, can cause alterations in the development of the stomatognathic apparatus. For this reason, myofunctional therapy can be a useful adjuvant treatment to orthodontics in subjects with myofunctional dysfunction. It was also observed that, if not corrected, these anomalies can cause relapses in patients who had previously underwent orthodontic treatment. Since in atypical swallowing the tongue is thrust forward, toward the front of the mouth, the most common dental anomaly is open bite; this

CATEGORIES	P-VALUE
Gender	0.80
Age	0.82
I sk-vert	0.58
II sk-vert	0.63
I sk-trasv	0.75
II sk- trasv	0.63
Rot type	0.93

TABLE 3 Statistical significance of Impact.

significantly affects the contraction of most of the orofacial musculature, as shown by several of our tests. All this can be correlated to aggravations (oral breathing, finger sucking, short lingual fraenum) that could worsen the alteration, therefore these bad habits have to be corrected as early as possible.

It is important to underline that myofunctional therapy, although not widely spread among orthodontists yet, can be very helpful if included in the orthodontic treatment.

## References

- › Cozza P, Mucedero M, Baccetti T, Franchi L. Treatment and post-treatment effects of Quad-Helix/Crib therapy of dentoskeletal open bite. *Angle Orthod*; 2007, 77(4): 640–645.
- › Ferrante A. *Manuale pratico di terapia miofunzionale*. Marrapese editore: Roma; 2004.
- › Ferrario VF, Sforza C, Colombo A, Ciusa V. An electromyographic investigation of masticatory muscles symmetry in normo-occlusion subjects. *J Oral Rehabil*, 2000; 27: 33-40.
- › Ferrario VF, Sforza C, Sartori, Ciusa V. The mechanical advantage of the masseter muscle in subject with different vertical and sagittal facial morphology. *Clin Orthod Res* 1999; 2: 162-170.
- › Ferrario VF, Sforza C, Schmitz JH, Ciusa V, Dellavia C. EMG assessment of chewing in adolescents with unilateral posterior crossbite. *Third Research Forum AIOP- 16th Int. Congress, Bologna, 1997*.
- › Ferrario VF, Sforza C, Serrao G, Colombo A, Schmitz JH. The effects of a single intercuspital interference on electromyographic characteristics of human masticatory muscles during maximal voluntary teeth clenching. *J Craniomandib Pract* 1999; 17: 184-188.
- › Ferrario VF, Sforza C. Coordinated electromyographic activity of the human masseter and temporalis anterior muscles during mastication. *Eur J Oral Sci* 1996; 104: 511-517.
- › Ferrario VF, Tartaglia G, Galletta A, Grassi G, Sforza C. The influence of occlusion on jaw and neck muscle activity: a surface EMG study in healthy young adults. *J Oral Rehabil* 2006; 33: 341-348.
- › Ferrario VF, Tartaglia GM, Luraghi FE, Sforza C. The use of surface electromyography as a tool in differentiating temporomandibular disorders from neck disorders. 2006 *Man Ther*, 12: 372-379, 2007; doi:10.1016/j.math.2006.07.013, on line 14 September 2006.
- › Ong HB. Treatment of a Class II division 1 anterior open bite malocclusion. *Singapore Dent J*, 2001; 24(1): 29-34.
- › Panigrahi P, Vineeth V. Biomechanical effects of fixed functional appliance on craniofacial structures. *Angle Orthod* 2009, 79(4): 668–675.
- › Saccomanno S, Antonini GL, D'Alatri L, D'Angelantonio M, Fiorita A, Deli R. Patients treated with orthodontic-myofunctional therapeutic protocol. *Eur J Paediatr Dent* 2012;13(3):241-243.
- › Serrao G, Sforza C, Dellavia C, Antinori M, Ferrario VF. Relation between vertical facial morphology and jaw muscle activity in healthy young man. *Prog Orthod* 2003; 4: 45-51.